

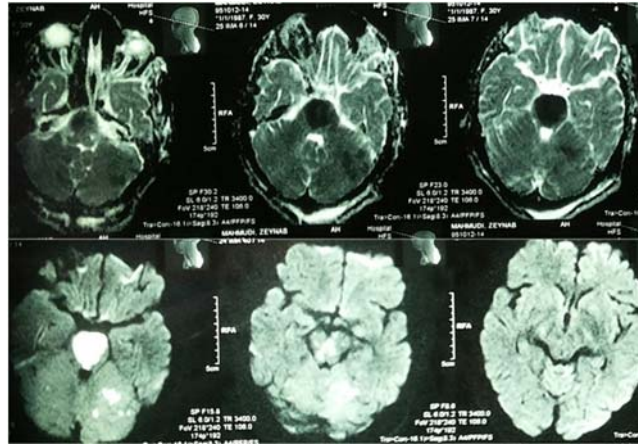Figure 1. MRI of the patient in the transverse view of the ADC map (top) and DWI (bottom) sequences indicates hypointensity and hyperintensity signal changes in the pons and parts of the left cerebellum suggesting acute ischemic infarction.

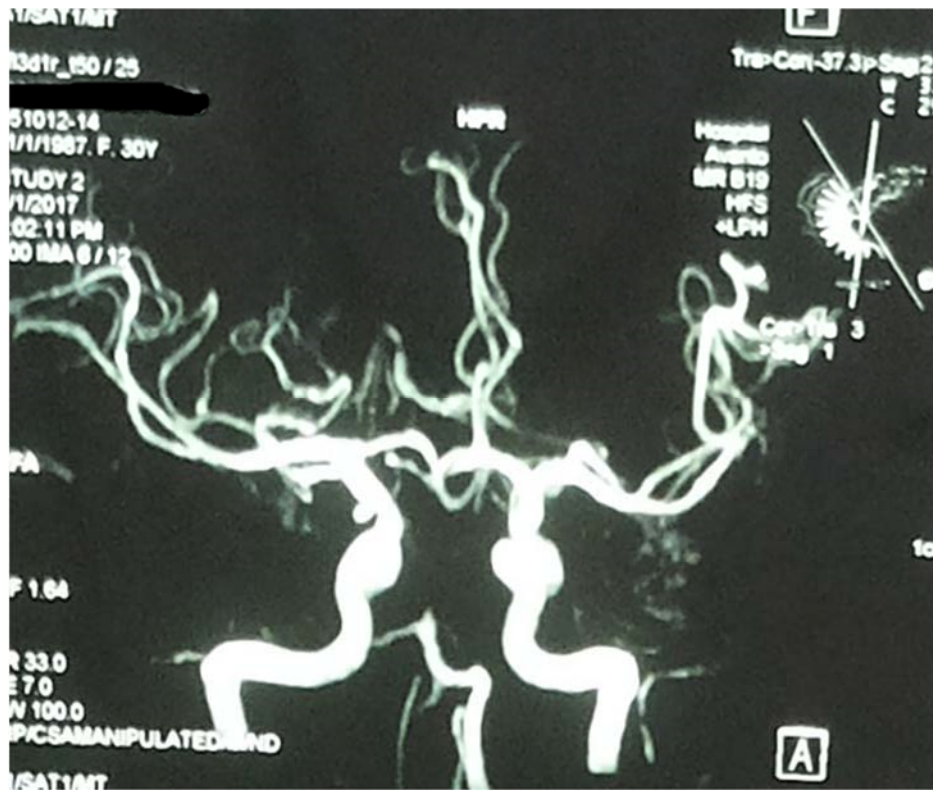


Figure 2. Magnetic resonance angiography shows no blood flow in the left vertebral artery.